



PATIENT

Sofia Cooper

SPECIES

Feline

BREED

DLH

SEX

FS

AGE

15 y

WEIGHT

7 lb

INTERPRETED BY

Keith Blass, DVM, MS,
DACVIM (Cardiology)

IMAGING PERFORMED BY

Graham Sager-
Gellerman, DVM

HOSPITAL NAME

Back Bay VC

REFERRING VET

Dr. Wheeler

INVOICE

DATE

5/14/26

PRESENTING CLINICAL SIGNS

Previously diagnosed with mild MR, TR, and AI. Doing well. No current cardiac medications. BNP 127.

ECHOCARDIOGRAPHIC FINDINGS

2D, M-mode, and Doppler study. This exam is compared to the one performed 10/21/25.

Left atrial size is normal. The mitral valve appears normal, though mild mitral regurgitation is present. Left ventricular wall thickness is normal. There is a moderator band (normal part of conduction system) inserting into the basilar portion of the interventricular septum. Left ventricular internal dimensions are normal. Left ventricular systolic function is normal. The aorta and aortic valve appear normal, though mild aortic insufficiency is present. Right atrial and right ventricular dimensions are normal. The tricuspid valve leaflets are mildly thickened, and a moderate jet of tricuspid regurgitation is present. The pulmonary artery and pulmonic valve appear normal, though trace pulmonic insufficiency is present. No shunting lesions are visualized. No heartworms are visualized. No pericardial effusion or cardiac masses are seen.

ECG during echo: Sinus rhythm

LA/Ao – 1.32 (prev. 1.44)

IVSd – 3.9 mm (prev. 3.8 mm)

LVPWd – 4.0 mm (prev. 3.8 mm)

LVIDd – 12.4 mm (prev. 11.6 mm)

LVIDs – 4.7 mm (prev. 5.5 mm)

FS – 62% (prev. 52.6%)

LVOT – 0.79 m/s (prev. 0.55 m/s)

RVOT – 1.17 m/s (prev. 0.50 m/s)

ASSESSMENT/RECOMMENDATIONS

This examination demonstrates no progressive changes compared to Sofia's previous echocardiogram. As such, her current risk for the development of left- and/or right-sided congestive heart failure and/or thromboembolic disease still appears to be low.

No therapy is recommended based on this exam.

A recheck echocardiogram is recommended in 9-12 months.



PATIENT

Sofia Cooper

SPECIES

Feline

BREED

DLH

SEX

FS

AGE

15 y

WEIGHT

7 lb

INTERPRETED BY

Keith Blass, DVM, MS,
DACVIM (Cardiology)

IMAGING PERFORMED BY

Graham Sager-Gellerman, DVM

HOSPITAL NAME

Back Bay VC

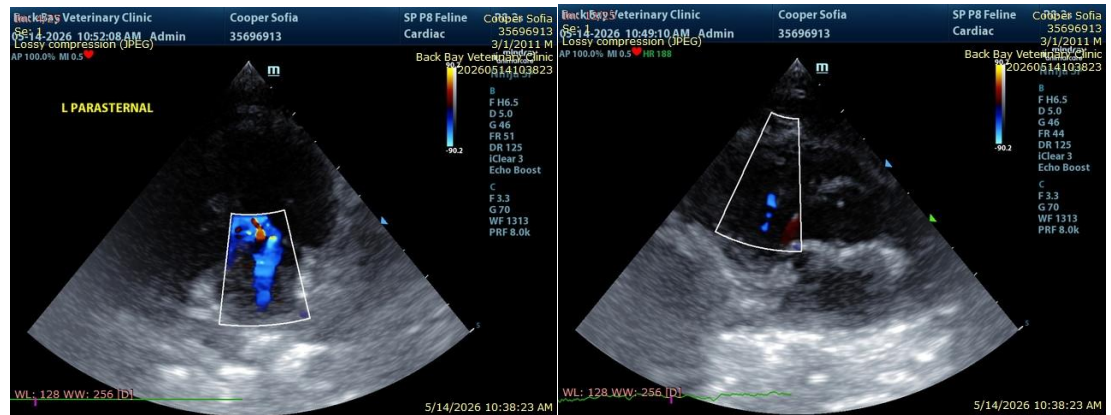
REFERRING VET

Dr. Wheeler

INVOICE

DATE

5/14/26



The information and recommendations provided are based on the images presented by the referring veterinarian/sonographer. No evaluation can be communicated regarding pathology that was not visible in the image/video clips provided.

Thank you for this referral. If the clinical or image interpretation does not parallel your findings or if I can be of any further assistance please contact me.

Keith Blass, DVM, MS, DACVIM (Cardiology) info@SonoPath.com